

## Anaesthetic management of children with Moya Moya Disease

P. Sawant, S. Sharma, U. Rangwala

Department of Paediatric Anaesthesia, BJ Wadia Hospital for Children, Mumbai, India

Corresponding author: S. Sharma, Department of Paediatric Anaesthesia, BJ Wadia Hospital for Children, Mumbai, India.

Email: [drsudivyasharma@gmail.com](mailto:drsudivyasharma@gmail.com)

### Key points

Moyamoya syndrome is a progressive occlusive cerebrovascular disorder that usually presents as recurrent strokes in children. The risk factors for perioperative complications, predominantly the cerebral ischemic events are: history of transient ischemic attacks, severity of disease, type of revascularisation procedure, significant reduction in hematocrit, intraoperative hypotension, intraoperative hypercapnia and reduction in circulating blood volume. We describe the anaesthetic management of a case undergoing surgery for moyamoya disease.

### Abstract

Moyamoya syndrome (MMD) is a progressive occlusive cerebrovascular disorder that usually presents as recurrent strokes in children. Distal internal carotid and basilar arteries gradually narrow, leading to proliferation of penetrating arteries, primarily at the base of the brain. Moyamoya in Japanese, means "something hazy, like a puff of cigarette smoke drifting in the air." Because of precarious cerebral circulation these patients represent an anaesthetic challenge. The risk factors for perioperative complications, predominantly the cerebral ischemic events in patients with MMD are: history of transient ischemic attacks, severity of disease, type of revascularisation procedure, significant reduction in hematocrit, intraoperative hypotension, intraoperative hypercapnia and reduction in circulating blood volume.<sup>1-3</sup>

We describe the anaesthetic management of a case undergoing surgery for moyamoya disease.

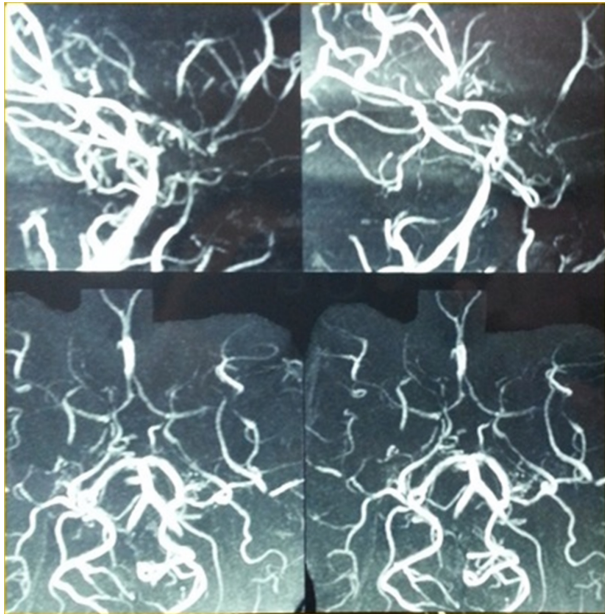
**Keywords:** ischaemia, stroke, moyamoya disease, hypocapnia, seizures

### Introduction

Moyamoya Disease is a rare cerebrovascular disease seen both in children and adults with variable progression and presentation. It could be congenital or acquired, the former linked to chromosome 17, and latter associated with head trauma, down's syndrome, neurofibromatosis, etc. It is characterized by angiographic evidence of progressive stenosis or occlusion of terminal portions of the internal carotid arteries and the proximal portion of the anterior and middle cerebral arteries. The posterior cerebral arteries may also be involved (Fig. 1).<sup>4</sup> This disease is more common in Asian populations, but even in Japan the overall incidence remains below 1 per 100,000. The male-to-female ratio has been shown to be 1:1.65 in one large series. The peak age of onset of moyamoya disease in the Asian population is bimodal, with an early peak occurring in the first decade of life, and a second peak in the fourth decade of life.

The compensatory collateral circulation that develops is weak and small, hence prone to haemorrhage, aneurysm and thrombosis. Clinical picture includes transient ischemic attacks, slow cognitive decline, headaches,

dizziness, seizures, visual impairment, involuntary movements, hemiparesis, monoparesis, sensory impairment or cerebral infarction. Cerebral angiography remains the gold standard to confirm the diagnosis of MMD.<sup>5,6</sup>



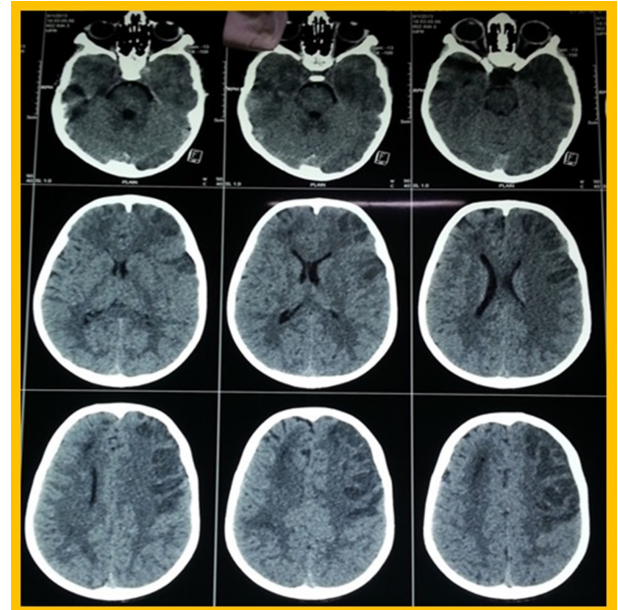
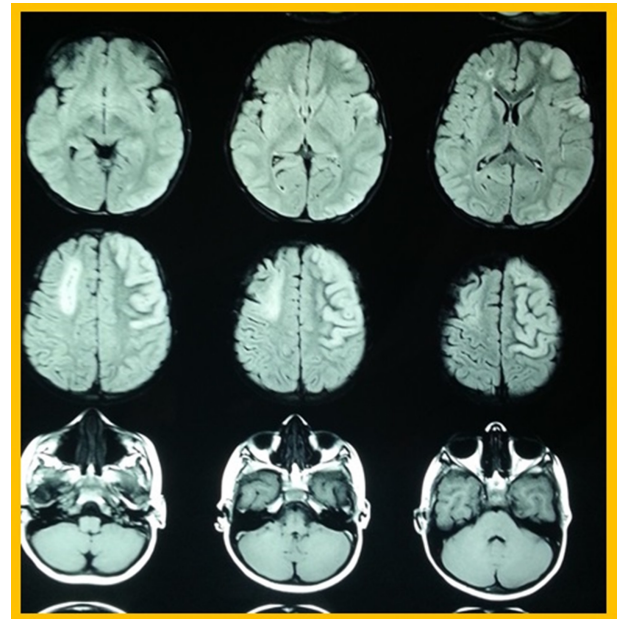
**Figure 1.** Angiographic picture of cerebral vasculature

### Case report

We present an interesting case of this rare disease and its anaesthetic implications. A 5 year old male child weighing 13 kgs gave history suggestive of right hemiparesis involving right side of face, upper limb and lower limb. There was associated slurring of speech, dribbling of saliva, inability to chew and occasional twitching of right leg or hand. The paresis was of sudden onset and preceded by fall on the ground. He was managed with drugs like aspirin, dexamethasone and mannitol. He improved over a period of one month with weakness persisting only in right upper limb and dribbling of food while eating at the time of presentation. A similar episode of weakness in left upper limb took place 3 months back which improved in 15 days with medication.

On further evaluation, computed tomography showed left frontoparietaotemporo infarct with perilesional edema and midline shift of 7mm (Fig 2a, 2b). Magnetic resonance angiography suggested significant narrowing

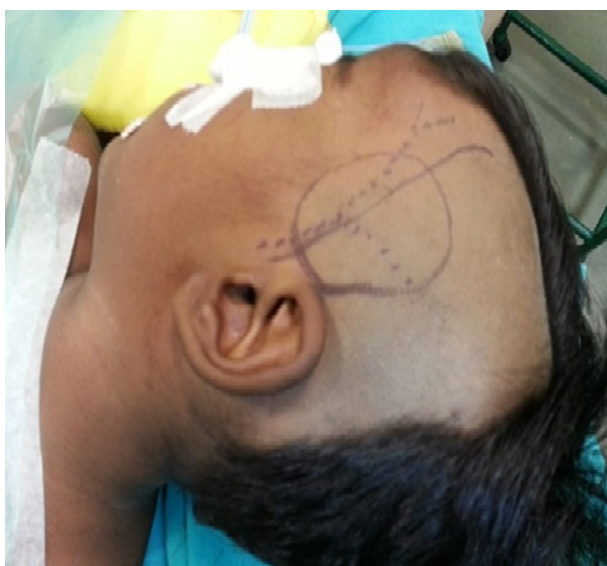and bilateral thickening of wall of internal carotid artery from their origin, most significant in petrous and cavernous portions. Diffuse significant stenosis of bilateral middle cerebral artery was seen. There was compensatory dilatation of posterior circulation and acute non haemorrhagic infarct in left frontal lobe involving white and gray matter.



**Figures 2a, 2b.** Computed Tomography showing left frontoparietal infarct with perilesional edema and midline shift of 7mm.

Encephaloduroarteriosynangiosis (EDAS) was planned for this child which involves placing superficial temporal artery over cerebral hemisphere expecting neovascularisation over a period of time supplementing the compromised blood supply.

The symptoms pertained to one hemisphere, hence unilateral surgery was planned (Fig. 3).



**Figure 3.** Surface marking of superior temporal artery prior to incision

The goals of our anaesthetic management were to avoid cerebral ischaemia which could be accomplished by maintaining normocapnia, normothermia, normovolemia, adequate depth of anaesthesia and maintenance of oxygen supply-demand ratio in brain. Recommended essentials for this surgery are invasive hemodynamic monitoring like central venous pressures and arterial blood pressure, good intravenous access, controlled ventilation, neurological monitoring and urine output measurement. Advanced monitors include electroencephalogram, bispectral index, myogenic and neurogenic evoked potentials, and near infra red spectroscopy. The child was premedicated with oral atropine 130µg and midazolam 5mg. Monitors like electrocardiogram, pulse oximeter, non-invasive blood pressure, temperature probe were applied. After preoxygenation with 100% oxygen for 3 minutes, intravenous induction was done

with titrated dose of propofol, 40 mg in total was given. Inj. Fentanyl 25µg was given for analgesia and obtundation of pressor response which leads to increase in CMR02. Among non depolarising muscle relaxants inj. Vecuronium was chosen because of its cardiostable and non-histamine releasing property. Smooth and gentle intubation was done with uncuffed 4.5 mm ID endotracheal tube and controlled ventilation done to maintain end tidal CO<sub>2</sub>. Maintenance drugs were isoflurane, air and oxygen. Cerebral protective effects of isoflurane have been proven during transient cerebral ischemia in adults undergoing carotid endarterectomy.<sup>7</sup>

Two large bore intravenous catheters were inserted 22G and 20G on each hand. The child was catheterised and urine output charting was done hourly. Positioning was done and pressure points were padded. Forced air warmer was used to keep the child warm. The mean blood pressure was maintained above 50 mmHg and EtCO<sub>2</sub> in range of 30-35mmHg. Blood loss was around 70 ml and was replaced. The surgery lasted 3 hours and urine output was 75ml. The child was given inj.fentanyl 15µg every hour, intravenous paracetamol 200mg was administered. The child was reversed with inj.glycopyrrolate 0.15mg and inj. Neostigmine 0.6mg and extubated after return of adequate, regular and spontaneous respiration. Inj. Morphine was administered for post-operative analgesia.

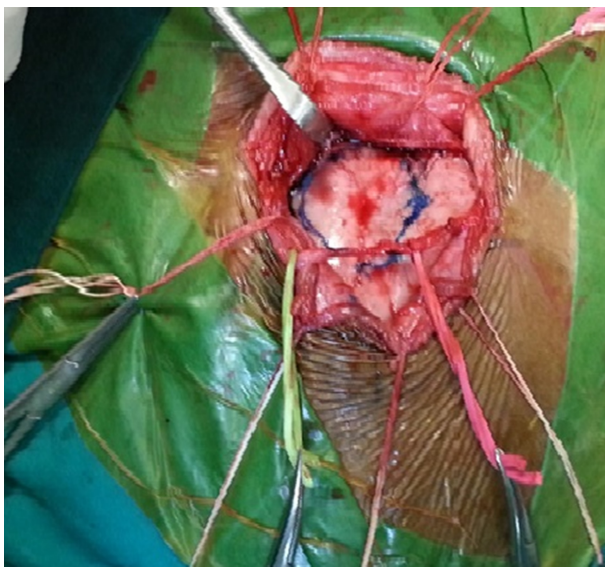
### Discussion

In MMD, the microscopic examination of these diseased vessels reveals intimal proliferation and thickening resulting in narrowing of the lumen, unlike atherosclerosis in which there is accumulation of fat and immune cells in damaged vessel wall. This disease primarily involves internal carotid artery, and often extends to the middle and anterior cerebral arteries. The diagnosis is suggested by CT, MRI and angiogram. These patients are mostly on medications like antiplatelets, anticonvulsants and steroids.

The goal of anaesthetic as well as surgical management is to maintain cerebral perfusion. Indications of surgery



include refractory symptoms due to ischaemia, haemorrhage, progressive neurological deficits and seizures. Surgical options include either direct anastomosis of superficial temporal artery to middle cerebral artery or placement of arteries over brain surface to re-establish new circulation as in EDAS (encephaloduroarteriosynangiosis), EMS (encephalomyosynangiosis) and multiple burr hole procedure. The surgical procedure done in our case was EDAS, which was first described by Matsushima et al. in 1981. It is designed to promote formation of collateral blood flow to the brain surface by utilizing the propensity of the ischemic brain to attract ingrowth of new blood vessels (Fig. 4).



**Figure 4.** Intraoperative surgical dissection

The cerebral blood flow (CBF) is less in patients with MMD than in healthy individuals. Adults seem to tolerate the reduction in CBF better than children because the cerebral metabolic oxygen consumption rate (CMR02) decreases with age. In a study on cerebral autoregulation in patients with moyamoya disease, Ogawa et al. reported that the autoregulatory response to hypotension was substantially diminished in children. Hence, hypotension is to be avoided. Because these children have significant mismatching of CBF and CMR02, they are also prone to developing neurologic deficits during hypotensive episodes. Therefore, a deep plane of anaesthesia should be provided that will decrease the relatively high CMR02 in children while maintaining adequate CBF.<sup>8,9</sup>

The behavior that involves hyperventilation and results in hypocarbia, such as blowing balloons, whistling, and crying, precipitates these symptoms. These patients frequently complain of headaches and may suffer intraventricular or subarachnoid hemorrhages from ruptured moyamoya vessels. During hyperventilation, hypocarbia causes constriction of the normal cerebral blood vessels. This results in decreased regional CBF and regional cerebral hypoxia in the diseased hemisphere due to “steal” from the moyamoya collateral vessels to the dilated cortical vessels after the termination of hyperventilation.<sup>10</sup>

The threshold for blood transfusion should be less than other surgeries as the oxygen balance is the prime concern. Also, hemodilution leads to decrease in oxygen carrying capacity of blood. Similarly, anemia if present, should be corrected.

The indirect procedures such as EDAS benefit the patient after few months, hence, the patient may remain symptomatic postoperatively.

### Conclusions

Neurosurgery for MMD is a high risk surgery as it involves the brain and its compromised circulation. The perioperative complications can be forfeited by ensuring cerebral perfusion and oxygenation. The disease is challenging as it presents at any age, with varied symptoms and unpredictable prognosis.

### References

1. Iwama T, Hashimoto N, Yonekawa Y. The Relevance of Hemodynamic Factors to Perioperative Ischemic Complications in Childhood Moyamoya Disease. *Neurosurgery* 1996; 38(6) 1120-1126.
2. Sakamoto T, Kawaguchi M, Kurehara K, et al. Risk Factors for Neurological Deterioration After Revascularization Surgery in Patients with Moyamoya Disease. *Anesth Analg* 1997;85:1060-5.
3. Sato K, Shirane R, Yoshimoto T. Perioperative factors related to the development of ischemic complications.

- tions in patients with moyamoya disease. *Childs Nerv System* 1997;13; 68-72.
4. Mineharu Y, Takenaka K, Yamakawa H, K. Inoue, H Ikeda, Y Takagi, K Nozaki et al. Inheritance pattern of familial moyamoya disease: autosomal dominant mode and genomic imprinting. *J Neurosurg Psychiatry* 2006; 77:1025-29.
  5. Sukuki J, Kodama N. Moyamoya disease – a review. *Stroke* 1983; 14:104-9.
  6. Chiu D, Shedden P, Bratina P, Grotta J. Clinical features of Moyamoya Disease in the United States. *Stroke* 1998; 29; 1347-1351.
  7. Michenfelder JD, Sundt TM, Fode N, Sharbrough FW. Isoflurane when compared to enflurane and halothane decreases the frequency of cerebral ischemia during carotid endarterectomy. *Anesthesiology* 1987;67:336-40.
  8. Ogawa A, Yoshimoto T, Suzuki J, Sakurai Y. Cerebral blood flow in moyamoya disease. Part 1: correlation with age and regional distribution. *Acta Neurochir (Wien)* 1990;105:304.
  9. Ogawa A, Nakamura N, Yoshimoto T, Suzuki J. Cerebral blood flow in moyamoya disease. Part 2: autoregulation and CO<sub>2</sub> response. *Acta Neurochir (Wien)* 1990;105:107-11.
  10. Soriano SG, Sethna NF, Scott RM. Anesthetic Management of Children with Moyamoya Syndrome. *Anesth Analg* 1993;77:1066-70.